CHAPTER 2

HISTOCHEMICAL OBSERVATIONS ON THE SUCCINIC DEHYDROGENASE AND CYTOCHROME OXIDASE ACTIVITY IN PIGEON BREAST MUSCLE

In this chapter is reported the result of a histochemical study undertaken to demonstrate the exact localization and distribution pattern of SDH and cytochrome oxidase activity in the pectoralis major muscle of the pigeon, by using improved methods.

Quantitative biochemical investigations on the two types of fibres are by no means easy, since the complete isolation of these fibres without damage appears extremely difficult if not impossible. Studies on the relative distribution and localization of metabolites and enzymes in these fibres by histochemical methods were therefore undertaken. George and Scaria (1956) demonstrated the presence of lipase in this muscle. George and Iype (1960) using improved histochemical method showed that lipase is localized in the red, fat-loaded fibres. George, Nair and Scaria (1958) showed that alkaline phosphatase is mainly confined to the same fibres, while George and Pishawikar (1959) have shown a higher concentration of ATPase in the white, glycogen-loaded fibres.

George and Scaria (1958c) in a histochemical study of dehydrogenases (succinic, malic, lactic, and glycerophosphate dehydrogenases) could not detect any of these in the broad white fibres. They suggested that these fibres in the pigeon breast muscle are a unique system in which none of the oxidative processes concerned with the above enzymes takes

place, and that these fibres therefore cannot be considered as analogous to the white fibres of the other vertebrate skeletal muscles studied. The method employed by these authors was that of Straus and others (1948), who used the colourless salt, TTC, as the hydrogen acceptor. Again in a quantitative study of the distribution pattern of SDH under aerobic conditions, in the different layers of the pigeon breast muscle , employing the method of Kun and Abood (1949), using TTC as the hydrogen acceptor, it was observed that the main bulk of the enzyme is restricted to the narrow red fibres (Chapter 1). It should be emphasized however, that these observations on the SDH activity in the pigeon breast muscle, made by histochemical and biochemical methods , were recorded under aerobic conditions . Within the limitations of the methods employed no significant enzyme activity was detected in the broad white fibres.

It is well known that in a living system the transport of hydrogen from succinate in the presence of the SDH system brings about the reduction of cytochrome c. This reduced cytochrome c is in turn oxidized by the molecular oxygen in the presence of cytochrome oxidase, which is the terminal enzyme in the entire respiratory chain. It was therefore thought necessary to examine the distribution of cytochrome oxidase in the two types of fibres. The classical 'Nadi' reaction was employed for the histochemical demonstration of the localization of the enzyme. The muscle sections thus treated revealed the presence of a detectable concentration

of cytochrome oxidase in the broad white fibres. The results thus obtained naturally question the validity of the earlier observations made regarding the absence of the SDH activity in the broad white fibres, and also regarding the specificity of the methods employed, both histochemical and biochemical.

It was therefore felt necessary to employ a more specific and sensitive method for the detection of the SDH system, so that it would be possible to detect histochemically even small concentrations of the enzymes. Indeed with certain modifications in the usual methods, under strictly anaerobic conditions, it was possible to demonstrate SDH activity in the broad white fibres, which had hitherto defied such an exposition.

Material and Methods

In order to ensure that only uniformly well developed *pectoralis major* muscle was used, well fed and fully grown, normal laboratory pigeons (*Columba livia*) of both sexes weighing between 280 to 340 gm. were used throughout.

Histochemical localization of the SDH system

The activity of the SDH system in the narrow red fibres could be demonstrated easily by the histochemical methods. But the broad white fibres in which the concentration of this enzyme is extremely low requires a more sensitive and improved method of treatment. The specificity and the sensitiveness of the method in turn would depend upon a number of factors. Several authors (Straus and others, 1948; Black and Kleiner, 1949; and Black and others, 1950) used TTC as the hydrogen

acceptor for the demonstration of SDH activity in animal tissues. Later Seligman and Rutenburg (1951), Padykula (1952), Rutenburg, Wolman, and Seligman (1953), and Whitehead and Weidman (1959), in their modified methods for the histochemical localization of SDH in various tissue sections, reported that under anaeroboc conditions the tetrazolium reduction was more rapid and intense, and some tissue sections which were not stained under aerobic conditions were stained under anaerobic conditions. The same observation was made by Kun and Abood (1949), Brodie and Gots (1951), Cooper (1955), and Padykula (1958) in the biochemical determination of SDH. Of the various tetrazolium salts used, TTC, BT, and NT, the latter was found to be most suitable for demonstrating SDH activity histochemically. It has also been preferred by Shelton and Schneider (1952), Padykula (1952, 1957), Cascarano and Zweifach (1955), Farber, Sternberg, and Dunlap (1956b) and Pearse (1960). Rosa and Velardo (1954), in a modified technique, suggested the incorporation of sodium cyanide into the incubation medium as an effective blocking agent for cytochrome oxidase and also as a trapping agent for any oxaloacetic acid that may be produced during the processing of the sections.

The whole literature on the histochemical methods employed for the demonstration of DPN diaphorase, TPN diaphorase, and the SDH system has been reviewed critically in a series of papers (Sternberg, Farber, and Dunlap, 1956; Farber, Sternberg, and Dunlap, 1956a, 1956b; Farber and Louviere, 1956; and Farber and Bueding, 1956). In a study of the

histochemical localization of specific oxidative enzymes, Farber and Louviere (1956) showed that the addition of any one of a number of soluble redox dyes to the incubation medium serves as a carrier between the enzyme and the tetrazolium salt, thereby increasing the rate of staining and making it possible to demonstrate the presence of enzymes which do not react directly with tetrazolium. Nachlas and others (1957) devised a simple method by the use of new tetrazole (nitro-blue tetrazolium) for the cytochemical demonstration of SDH system. Pearson (1958) used nitro-neotetrazolium chloride. In the present investigation, the neotetrazolium chloride was used mainly because of the non-availability of the nitro-blue tetrazolium during the course of the work. Nevertheless, neotetrazolium chloride, in a modified incubation medium, showed quite satisfactory results. The TTC method of Straus and others (1948) was also tried for comparing the results obtained by the modified method which successfully demonstrated the presence of the SDH system in the broad white fibres of the pigeon breast muscle. The modifications were mainly in the composition and use of the incubation medium based on the methods reported by Seligman and Rutenburg (1951), Padykula (1952), Rutenburg, Wolman, and Seligman (1953), Rosa and Velardo (1954), Farber and Louviere (1956), and Farber, Sternberg and Dunlap (1956b). All the chemicals used in the study were of C.P. grade and purchased from Merck and Co. NT was obtained from Nutritional Biochemicals Corporation. The composition of the incubation medium used

(in a total volume of 6 ml.) was as follows:

PO_4 buffer (0.1 M, pH 7.6).....2.5 ml.

Na succinate (0.5 M, brought to pH 7.6).....0.6 ml.

$CaCl_2$ (0.004 M).....0.5 ml.

$AlCl_3$ (0.004 M).....0.5 ml.

$NaHCO_3$ (0.6 M, freshly prepared).....0.3 ml.

NaCN (0.03 M, brought to pH 7.6).....0.5 ml.

NT (3 mg./ml., freshly prepared).....1.0 ml.

$MgSO_4$ (0.005 M).....0.05 ml.

Methylene blue (2 mg./ml.).....0.05 ml.

The incubation mixture was boiled in a small vial to remove dissolved oxygen. The vial was stoppered immediately. After cooling, the mixture was stored in a bath maintained at 37° C. till the sections were ready for incubation.

For each experiment a bird was decapitated and bled. A piece of muscle 1 cm. in length, consisting of the complete depth of the muscle, was immediately cut out and mounted on the stage of a carbon dioxide freezing microtome. The muscle block was frozen hard as quickly as possible so as to avoid the formation of ice crystals and distortion of the tissue. Sections between 20 to 40 μ thick were cut and floated in ice cold phosphate buffer for nearly 10 minutes in order to remove the endogenous substrates from dehydrogenase activity. The sections were then transferred quickly to the vial containing the incubation medium. The method followed for creating the anaerobic conditions required for the experiment was that of Padykula (1952). The vial with Padykula's arrangement was

placed in a bath maintained at 37° C. A gentle bubbling of nitrogen was continued during incubation. The incubation was carried out for 15 to 60 minutes as desired. After incubation the sections were washed thoroughly in phosphate buffer, fixed in 10 % buffered neutral formalin at 4° C. for nearly 2 hours and after washing mounted in glycerogel. The preparations were immediately examined under a microscope and photographed.

In order to verify the specificity of the SDH activity, two sets of control experiments were conducted. In one the sections from cold phosphate buffer were incubated anaerobically in the absence of succinate. In the other the sections were treated with malonate. Supplementary experiments were performed on frozen sections with TTC or NT as the hydrogen acceptor, under aerobic or anaerobic conditions, without the intervention of activators or the soluble redox dye.

To rule out the possibility of any false localization of SDH activity resulting from diffusion, which is liable to occur in a mixed muscle like the pigeon pectoralis where the two types of fibres exist side by side, a simple technique was followed. In each experiment a small strip of muscle from a freshly-killed pigeon was cut and transferred to a 0.9 % cold NaCl solution. Immediately after this the two types of fibres from the mixed muscle were isolated by teasing them out by a pair of fine watch-maker's forceps under a stereoscopic dissection microscope and treated separately for the demonstration of SDH activity by the method mentioned above.

Histochemical localization of cytochrome oxidase

The classical 'Nadi' reaction, employing a mixture of a-naphthol and dimethyl-p-phenylene diamine hydrochloride, demonstrates the presence of cytochrome oxidase in cells (Moog, 1943; Borei and Bjorklund, 1953). A critical review of the merits and demerits and the specificity of the 'Nadi' reaction for the histochemical demonstration of cytochrome oxidase has been given by Gomori (1952), Crawford and Nachlas (1958), Nachlas, Crawford, Goldstein, and Seligman (1958), Burstone (1959) and Pearse (1960). In the present study the following method was adopted from the reports of Moog (1943) and Nachlas, Crawford, Goldstein and Seligman (1958) for demonstrating histochemically cytochrome oxidase in fresh frozen sections of the pigeon breast muscle. The Nadi mixture used was composed of the following reagents:

PO_4 buffer (0.1 M, pH 7.4).....3 ml.
a-naphthol (1 mg./ml. in 1 % NaCl).....5 ml.
Dimethyl-p-phenylene diamine hydrochloride
(1 mg./ml. in 1 % NaCl).....5 ml.
Cytochrome c (3 mg./ml.).....2 ml.

All the reagents were freshly prepared just before use, mixed together, and filtered. Cytochrome c was omitted from the medium in the routine experiments unless required specifically. Addition to the incubation medium of a catalase and an inhibitor for dehydrogenase was not found necessary.

As mentioned in the case of SDH activity, fresh frozen sections of the muscle were placed quickly in 0.9 % cold NaCl

solution and then incubated in the freshly prepared Nadi mixture at room temperature for 5 to 15 minutes as required. Control sections were treated with sodium azide and sodium cyanide as recommended by Moog (1943). After incubation, sections were washed thoroughly in 0.9 % NaCl solution and mounted in saturated potassium acetate. Photomicrographs were taken immediately. It was observed, however, that the sections mounted in potassium acetate and maintained at 4° C. lasted for a number of days without any visible change in colour or pattern of granules.

As mentioned in the case of SDH, the two types of fibres were isolated and treated separately for cytochrome oxidase activity. In order to compare the histochemically demonstrable granular pattern of the SDH system and cytochrome oxidase with mitochondrial staining, sections of the pigeon breast muscle were stained by Janus green B and also by Altman's aniline fuchsin method as described by Gray (1954).

Observations

Distribution of succinic dehydrogenase system

When frozen sections were incubated aerobically without the addition of activators or soluble redox dye, with TTC as hydrogen acceptor, a regular distribution pattern of the SDH system was observed in the narrow red fibres. These red fibres were stained within 10 minutes while the broad white fibres did not show any detectable activity of SDH even after incubation for 1 hour (Fig. 1). But when the sections were treated

with the modified incubation medium under strictly anaerobic conditions with NT as indicator, the localization of the enzyme in both types of fibres was observed at the cytochemical level (Figs. 2, 3 and 4). SDH activity was revealed in the red narrow

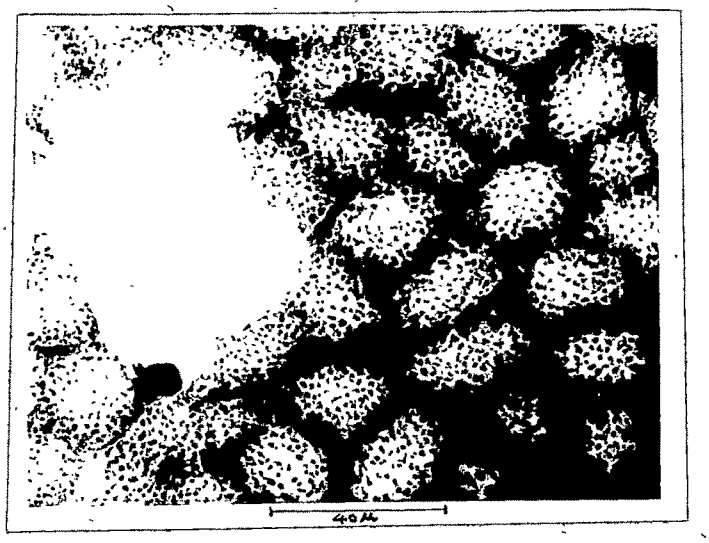

Fig. 1. Microphotograph of T. S. of pigeon breast muscle showing the distribution of SDH in the two types of fibres, treated under aerobic conditions with TTC. Note the unstained broad white fibres. Incubation period 1 hour.



Fig. 2 Fig. 3

Figs. 2 and 3. Microphotographs of L. S. passing through the narrow red fibres of the pigeon breast muscle , showing the histochemically demonstrable SDH-positive granules arranged linearly along the myofibrils and representing more or less the distribution pattern of mitochondria. Incubation period 1 hour.

fibres within 10 minutes as fine bluish-violet diformazan granules distributed in a most regular pattern in both transverse and longitudinal sections. After an incubation period of 15 to 30 minutes the presence of SDH was revealed in the white fibres by lighter bluish-violet diformazan granules, which were of course, smaller and far fewer than those of the narrow red fibres (Figs. 4, 5 and 6). A clear



Fig. 4. Microphotograph of the longitudinal section passing through the broad white fibre of the pigeon breast muscle, showing the distribution and localization pattern of histochemically demonstrable SDH-positive granules arranged linearly along the myofibrils. The granules are far fewer and smaller than in the narrow red fibres. Incubation period 1 hour.

picture of the exact distribution of the granules was obtained in longitudinal sections, where red and white fibres were side by side. The sarcoplasm of the muscle fibres was stained slightly pink and also contained sharp bluish-violet diformazan

granules, which were arranged in a definite linear fashion between the unstained myofibrils (Figs. 2, 3 and 4). The localization of the SDH system, which could not be demonstrated in the broad white fibres by ordinary methods, thus became visible (Table 1).

Table 1

Histochemically demonstrable succinic dehydrogenase in the broad white fibres of the pigeon breast muscle

Expt.	Incubation mixture in a final volume of 6 ml., pH 7.6	Degree of staining in 1 hour	
		aerobic	anaerobic
1	Medium A		
	TTC + succinate + PO_4 buffer	0	±
2	Medium B		
	NT + succinate + PO_4 buffer	+	+ +
3	Medium C		
	NT + succinate + PO_4 buffer + activators (Ca^{++}, Al^{+++}, Mg^{++}, and HCO_3^-) + NaCN	+ +	+ + +
4	Medium D		
	Reagents of medium C + methylene blue	+ +	+ + + +

0 = No detectable staining;
± = Trace of detectable staining;
+, ++, +++, ++++ = Relative degrees of staining under different conditions.

In addition to the diformazan granules in the sections, a diffused red colour was visible in most of the narrow red fibres. This probably represented the partially reduced form of the dye (monoformazan), or the dye dissolved in the fat which is quite abundant in the narrow red fibres. The inter-fascicular fat was stained uniformly deep red and no granules were visible. Thus the sharp diformazan granules with the distinct bluish-violet colour showed the exact sites of the localization of the SDH system in the two types of fibres (Figs. 5 and 6).

Fig. 5



Fig. 6

Figs. 5 and 6. Microphotographs of transverse and longitudinal sections respectively of the pigeon breast muscle, showing the distribution and localization pattern of SDH in the two types of fibres. The narrow red fibres show a markedly greater deposition of diformazan granules than the broad white fibres. Note the smaller diformazan granules in the broad white fibre. Incubation period 30 minutes.

Fresh frozen sections at different levels in the whole depth (ventral face to dorsal face) of the pigeon breast muscle when treated for the SDH system, showed that in each individual narrow and broad fibre, the degree of staining for the enzyme was more or less the same in the correspondimg fibres throughout the depth of the muscle. In the narrow red fibres relatively more granules were observed towards the periphery. TTC was not found suitable for the low enzyme activity in the broad white fibres because of the diffused pale red colour it formed during enzymic reduction, which did not give a sharp contrast under the microscope. On the other hand, NT, because of the sharp blue violet granules it formed, was found more suitable for such studies.

Distribution of cytochrome oxidase

The distribution pattern of cytochrome oxidase by the Nadi reaction showed a close resemblance in all respects to that of SDH. Cytochrome oxidase activity was indicated by the formation of indophenol blue granules resulting from the oxidative coupling of a-naphthol and dimethyl-p-phenylene diamine hydrochloride in the presence of cytochrome c, in both the narrow and the broad fibres of the pigeon breast muscle (Figs. 7 and 8). The diffusibility and the solubility in fat of the final dye, indophenol blue, was observed in the form of uniform violet colour. This violet staining could easily be distinguished from the actual sites of the localization of cytochrome oxidase in the form of dark blue indophenol granules. The inter-fascicular fat was also stained

deep violet. During a short incubation period without added cytochrome c no detectable colour was observed in the broad white fibres. However, blue granules were seen in these fibres when cytochrome c was introduced into the incubation medium.



Fig. 7

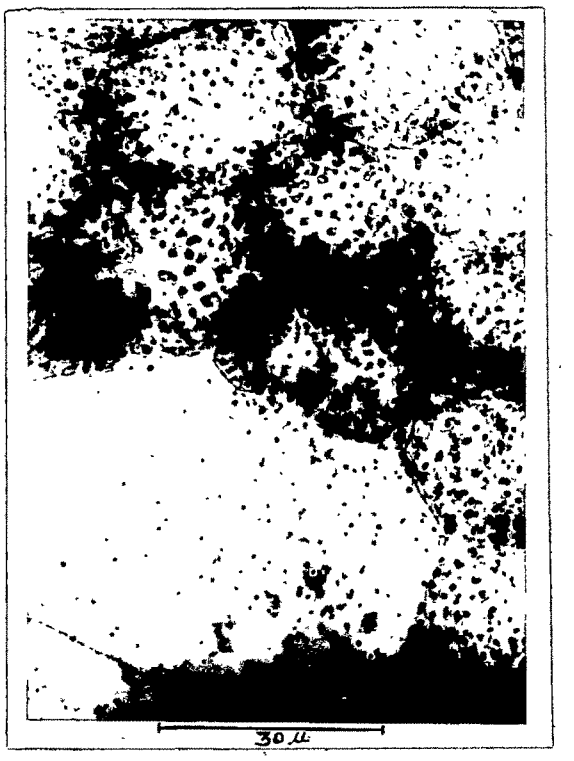

Fig. 8

Figs. 7 and 8. Microphotographs of the transverse and longitudinal sections respectively of the pigeon breast muscle, showing the localization and distribution pattern of cytochrome oxidase. Note the similarity in the size, distribution, and localization pattern of indophenol blue granules with that of the diformazan ones (Figs. 5 and 6). Incubation period 10 minutes.

The two types of fibres isolated under a dissecting microscope and separately treated histochemically for SDH and cytochrome oxidase, showed the same distribution pattern of the granules as was observed in the sections.

The longitudinal and transverse sections of the pigeon breast muscle stained for mitochondria, SDH, and cytochrome

oxidase all showed close similarity as regards the actual sites of staining. On careful observation it was found that the size and distribution pattern of the diformazan as well as indophenol blue granules more or less coincided with those of the mitochondria.

Discussion

The above observations have shown that the two types of muscle fibres in the pigeon pectoralis, when treated for SDH and cytochrome oxidase, stain with different intensity. A distinct pattern of granules representing the succinoxidase system in the sarcoplasm between myofibrils more or less coincides with the pattern of the mitochondria. It can therefore be concluded that the actual sites of localization of the SDH system is in or near the mitochondria, and the histochemically demonstrable diformazan and indophenol blue granules do represent the pattern of mitochondrial distribution in pigeon breast muscle . It is well known that SDH may be demonstrated histochemically in or near the mitochondria (Goddard and Seligman, 1952, 1953; Nachlas and others, 1957; Scarpelli and Pearse, 1958). The same applies in the case of cytochrome oxidase, as the activity of the SDH system is linked with the cytochrome oxidase. The considerably less SDH activity observed in the broad white fibres is obviously due to their low mitochondrial content. This contention is supported by both biochemical (Hogeboom, Schneider and Palade, 1948; Harman, 1950; Paul and Sperling,

1952; Harman and Osborne, 1953; Chappell and Perry, 1953) and electron microscopic studies (Barnett and Palade, 1957; Sedar and Rosa, 1958), which have shown that SDH is exclusively present in the mitochondria. The granules thus made visible in the broad white fibres of the pigeon breast muscle are to be regarded as mitochondria. These have not been reported by previous workers.

The narrow red fibres possess a large volume of sarcoplasm and numerous granules of large size (Figs. 2 and 3), while the broad white fibres have considerably less sarcoplasm and possess much fewer, smaller granules (Fig. 4). Further details regarding the actual size and exact position of these smaller SDH-positive granules in the broad white fibres could only be made available by using the electron microscope. The myofibrils of both the red narrow and the broad white fibres do not show any detectable positive reaction for the SDH system. The absence of this system in myofibrils has been shown biochemically by Harman and Osborne (1953) in a pure suspension of myofibrils.

In fresh, unfixed, frozen sections, all granules representing the sites of SDH activity are spherical and of about the same size in fibres of the same type (larger in the red fibres than in the white). Various authors (Harman and Osborne, 1953; Kitiyakara and Harman, 1953; Weinreb and Harman, 1955; and Harman, 1955) have distinguished two types of cytochondria, the spherical forms as sarcosomes and the large elongated ones as mitochondria. Both are said to be linearly

arranged alomg the myofibrils in the red fibres of the pigeon breast muscle. In the fresh frozen preparations, however, only spherical granules in both types of fibres were detected: the elongated ones (Harman's mitochondria) were not found (Figs. 2 and 4). Picture similar to this (Fig. 2) was obtained by Harman also (Fig. 1, 1955). His claim of the existence of the rodlet mitochondria does not appear convincing. Evidence from electron microscopy in spport of his contention (his Figs. 2 and 3) also does not appear convincing. In the circumstances one is inclined to believe that the spherical granules in both the types of fibres are to be regarded as mitochondria in the general sense.

When frozen sections were incubated in Nadi mixture with added cytochrome c, an increase in cytochrome oxidase activity was observed. This suggests that the broad white fibres possess a very low concentration of cytochrome c, whereas the narrow red fibres seem to be rich in it. In a similar study Katchman and Shooter (1955) and Maruyama and Moriwaki (1957) have shown, in the pigeon breast muscle and in the thoracic muscle of the honey bee respectively, the dependence of succinoxidase activity on cytochrome c concentration. It seems probable that the low succinoxidase activity in the broad white fibres of the pigeon breast muscle is associated with the higher glycogen deposition. Thus the characteristic glycogen load may be a result of poor oxygen supply, leading to anaerobic metabolism.

These observations throw some more light on the earlier

observations made regarding the occurrence of oxidative enzymes in the two types of fibres. The presence in the white fibres of a few smaller granules, responding positively to tests for SDH and cytochrome oxidase, indicates the existence of some sort of cytochondria in them with a very low oxidative metabolism, even less than that of the white fibres of the other vertebrate skeletal muscles. It should, however, be emphasized that the white fibres of the pigeon breast muscle are not fundamentally different from the white fibres of the other vertebrate skeletal muscles. On the contrary, it can be concluded from these studies that in such a mixed type of muscle as the pigeon pectoralis , the broad white fibres, chiefly loaded with glycogen and with very low concentrations of oxidizing enzymes, function mostly anaerobically and in all probability are meant for quick and sudden contraction for a short duration, whereas the narrow red fibres loaded with fat and with very high concentrations of the Krebs cycle enzymes, are used for sustained contraction.