CHAPTER 8

HISTOCHEMICAL INVESTIGATION ON NORMAL AND DYSTROPHIC HUMAN MUSCLE

The atrophic changes such as degeneration of fibres, alterations in fibre size and increase in muscle nuclei, proliferation of fatty and connective tissues in skeletal muscles induced experimentally by disuse and denervation, are similar in many respects to those described for human muscular dystrophy. However, a number of dissimilarities with respect to histochemical and biochemical changes in certain enzymatic activities in muscle, are known to exist in the various forms of atrophies in animals and in human muscular dystrophy.

That many of the vertebrate skeletal muscles irrespective of colour consist of two different types of contracting systems viz. pale (white) tetanic and red tonic fibres which are structurally and metabolically adapted for the respective functional diversity, is well known. In our previous investigations on the denervated and immobilized pigeon breast muscle (Chapter, 1, 2 and 6), diametrically opposite changes have been shown to occur in a large number of tetanic and tonic fibres. Besides these changes, intra- and extra-cellular infiltration and accumulation of lipids and increase in the connective tissue, all of which constitute the primary cause for the degeneration of the muscle cells, were clearly seen. Changes in enzymatic activities involved in lipid and carbohydrate metabolisms which might be responsible for the increased

rate of synthesis and low utilization of lipids, thereby promoting its lipid accumulation in the muscle, have also been brought to light.

The above findings on the denervated pigeon breast muscle have stimulated the present study on the human dystrophic muscle. The investigations reported here were undertaken with a view to understand the various biochemical changes taking place in the red, tonic and the white, tetanic fibres in relation to carbohydrate and lipid metabolisms.

Materials and Methods

Muscle biopsies were obtained from male muscular dystrophy patients admitted to Shri Sayaji General Hospital, Baroda. Six of the patients (7 to 14 years), had progressive muscular dystrophy, and one (26 years) of the limb girdle type. For controls similar biopsies taken from three males (10 to 24 years) who were free from any muscular disorders were obtained from the emergency Orthopaedic ward of the hospital. The muscle sample used was removed under local anaesthesia and in all the former six cases, a portion of the gastrocnemius was used while in the seventh case, the gluteus maximus was taken. For the controls (normal muscle), the muscle examined were the same as mentioned above. The muscle samples on removal were wrapped in thin aluminium foil and immediately put into liquid air for about 2 minutes. They were then transferred to a cryostat (International Harris) at -20°C. and stored in protective containers till the time of use. Sections of 6 μ thick were cut, affixed to coverslips,

finger thawed and air dried for the various histochemical observations. Some samples were fixed in Bouin's fluid, cleared in xylene, embedded in paraffin and sectioned at 10 μ. These were stained eventually in haematoxylin and eosin for histological observations.

The histochemical reactions studied included those for glycogen (PAS technique), fat (Sudan black B, Nile blue sulphate), phosphorylase, UDPG-glycogen synthetase (Takeuchi, 1960), succinic dehydrogenase , (George and Talesara, 1961), β-hydroxybutyric dehydrogenase (Pearse, 1960), dihydrolipoic dehydrogenase (Balough, 1965), pentose cycle dehydrogenase (Pearse, 1960), Tween 20 esterase, Tween 85 lipase (Pearse, 1960, Bokdawala and George, 1965), acid and alkaline phosphatases (Gomori, 1952, Burstone, 1958) and ATPase (Wachstein and Meisel (1957). The acid and alkaline phosphatase reactions were studied simultaneously employing β-glycerophosphate and azo dye techniques. The procedure for the rest of the histochemical reactions were similar to that described elsewhere (Chapter 6).

Evaluation of the histological and histochemical preparations was carried out by microscopic examination ~~and~~ and recorded photomicrographically. Comparisons were made with the control sections. The duration of the incubation period for obtaining satisfactory staining reaction in the case of the dystrophic tissue was also used as control. As a result of this many of the histochemical reactions in the normal muscle showed negative results due to the incubation

period being short and in some other cases the normal muscle showed intensive staining reactions due to prolonged incubations as was the case with the dystrophic muscle. Therefore, in the ~~the~~ presentation of the photomicrographs of many of the histochemical reactions of the normal muscle has been considered unnecessary.

Results

Normal human muscle: The normal human biopsies were studied with a view to compare the results with those obtained for dystrophic samples. In the normal used as controls the fibres appeared to be polygonal in shape, there being no striking difference in the diameter of the individual fibres.

With regard to the metabolite concentration, the load of glycogen in the broad(white) fibres was greater than in the narrower (red) fat loaded ones, but not high enough to afford a sharp distinction between the fibres. Phosphorylase activity was higher in the larger fibres, whereas all the dehydrogenases studied were highly active in the narrow ones. Tween 20 esterase was localized predominantly in the narrow fibres. Sections incubated for lipase, acid and alkaline phosphatases however, gave a faint positive reaction. ATPase activity was higher in the narrow fibres at pH 7.2.

Dystrophic human muscle: In dystrophic muscle striking changes were noted as a result of myopathy. There was significant reduction in the total number of muscle fibres in a single unit area and replacement of the fibres by fat and fibrous

connective tissue was typical characteristic in all the cases. There was considerable variation in shape and size (diameter) of the fibres. Myopathic muscle fibres appeared rounded in shape instead of polygonal as in the normal. Diameter of the fibres usually ranged from 80 to 135 μ and 35 to 55 μ in the case of the white and red fibres respectively. However, there were many instances in which some muscle fibres were enlarged (150 μ) and others small (25 μ). Apparent longitudinal splitting or pairing of such larger fibres was often seen. Few fibres were basophilic and contained prominent nuclei. These nuclei were more in number and usually seen in rows more towards the interior of the fibres. Many of the fibres were acidophilic and some such fibres showed signs of hyalinization and degeneration. In three of the advanced cases of dystrophy there was an encroachment of connective tissue with fat replacing the muscle fibres more or less completely leaving only a few scattered fibres.

Glycogen : The concentration of glycogen was markedly high in all the fibres. Connective tissue also gave a positive staining reaction, but not as intense as of the fibres.

Fat : The gross concentration of intracellular fat was much reduced, though few of the narrow fibres were fat loaded. Large quantities of extracellular and extrafascicular fat were present.

The extracellular fat showed a positive staining reaction for neutral lipids and the intracellular fat for phospholipids or acid lipids. Mitochondria and the sarcoplasmic

reticulum were stained positively with the periphery of the fibres showing a more intense staining.

Phosphorylase: Some of the narrow and some of the broad fibres gave intense positive reaction, while the rest of the fibres gave a low or negative reaction. The fibres which gave a positive reaction for the enzyme activity presented a greater intensity of the reaction than that of the fibres of the normal muscle.

Uridine diphosphate glucose (UDPG)glycogen transglucosylase (Glycogen synthetase): ~~Sections~~ UDPG glycogen synthetase gave positive reaction in five of the cases and negative in two of the cases studied. Among the five cases the intensity of the staining reaction was uniform in many of the red fibres while in some cases few of the red fibres showed darker staining and the white fibres showed a light positive reaction. In all the reactive fibres the enzyme activity was revealed in the sarcoplasmic reticulum.

Pentose cycle dehydrogenases: Increased enzymatic activity for both glucose-6-phosphate dehydrogenase and 6-phosphogluconate dehydrogenase of the pentose cycle was noted in the red as well as the white fibres. However, 6-phosphogluconate dehydrogenase was comparatively less than the glucose-6-phosphate dehydrogenase. The activity of both the dehydrogenases was intense at the periphery including the sarcolemma. Sarcoplasmic reticulum and mitochondria showed a positive reaction. Enzyme activity was also discernible in the connective tissue.

β-hydroxybutyric dehydrogenase: The activity of this enzyme is closely similar to that of the pentose cycle dehydrogenases,

but the intensity of the staining reaction is greater. The red fibres showed greater enzyme activity. The sarcoplasmic reticulum and mitochondria were stained but the peripheral region including the sarcolemma was more intensely stained.

Succinic dehydrogenase (SDH): The enzyme activity was greater in the red fibres. Degenerated regions displayed a negative reaction whereas connective tissue and blood vessels were positive.

Dihydrolipoic dehydrogenase (DLD): The enzyme reaction was more intense in the narrow, red fibres. The white fibres not only showed less diformazan deposits but was also not uniform in distribution in all the white fibres. The sarcoplasmic reticulum was stained and both the types of fibres showed higher enzyme activity towards the periphery. In the degenerated regions however, there was hardly any activity of the enzyme.

Lipase and Tween 20 esterase: The lipase activity was practically negligible in all the fibres, whereas for Tween 20 esterase a relatively faint activity was discernible in the narrow fibres. The degenerating fibres as well as connective tissue however, showed high esterase activity.

Acid and alkaline phosphatases: Low concentrations of these enzymes were detected in all the fibres though some fibres showed slightly greater activity than the others. The connective tissue, sarcolemma, nuclei and blood capillaries however, showed a higher level of enzyme activity. The sarcoplasmic reticulum was slightly stained for acid phosphatase.

ATPase: ATPase activity at pH 7.2 was higher in the red fibres

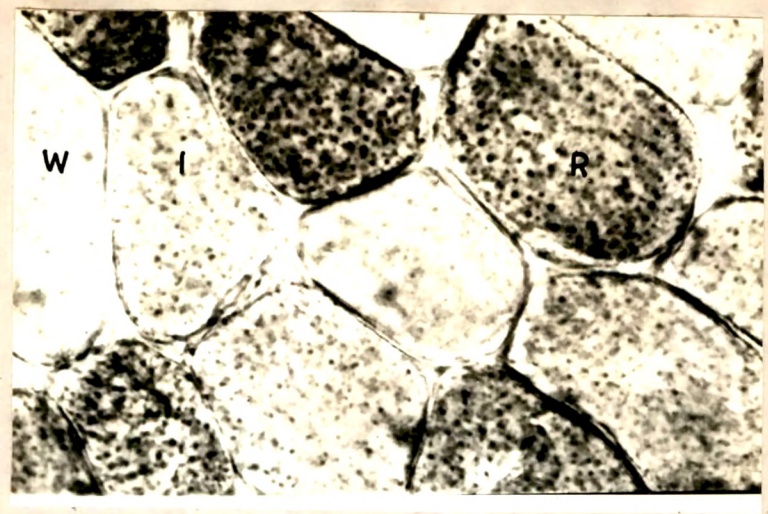

Fig. 1. T.S. of normal human gluteus muscle stained with Sudan Black B. for fat. Three types of fibres are visible. Darkly stained red fibres(R), poorly stained white fibres (W) and intermediate (I). 640 X.

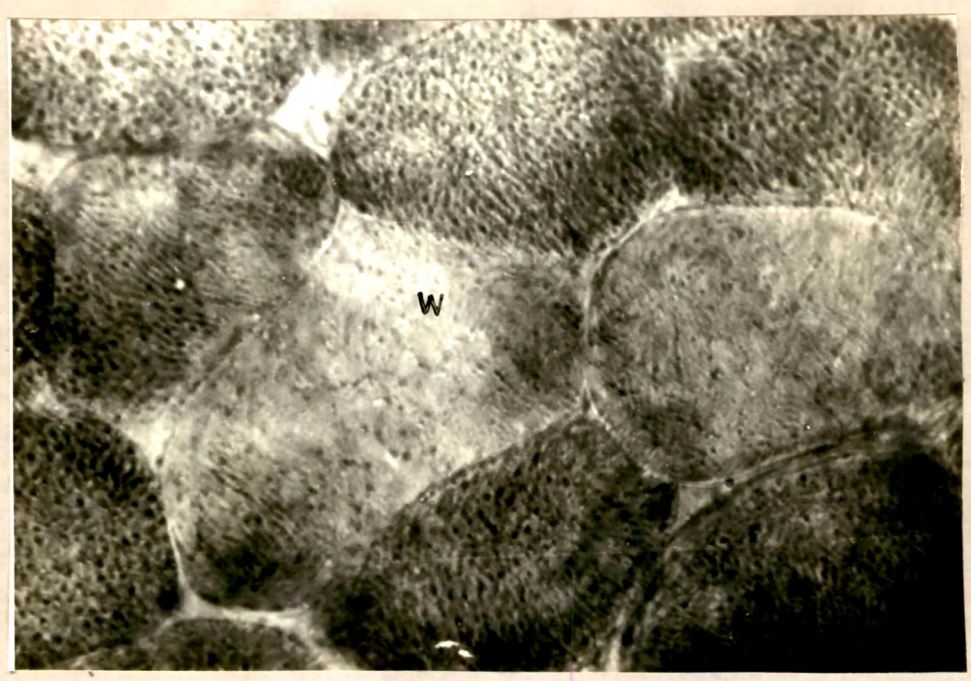

Fig. 2. T.S. of normal human gluteus muscle stained to demonstrate succinic dehydrogenase activity. Diformazan deposits are less in white fibres (W). 640 X.

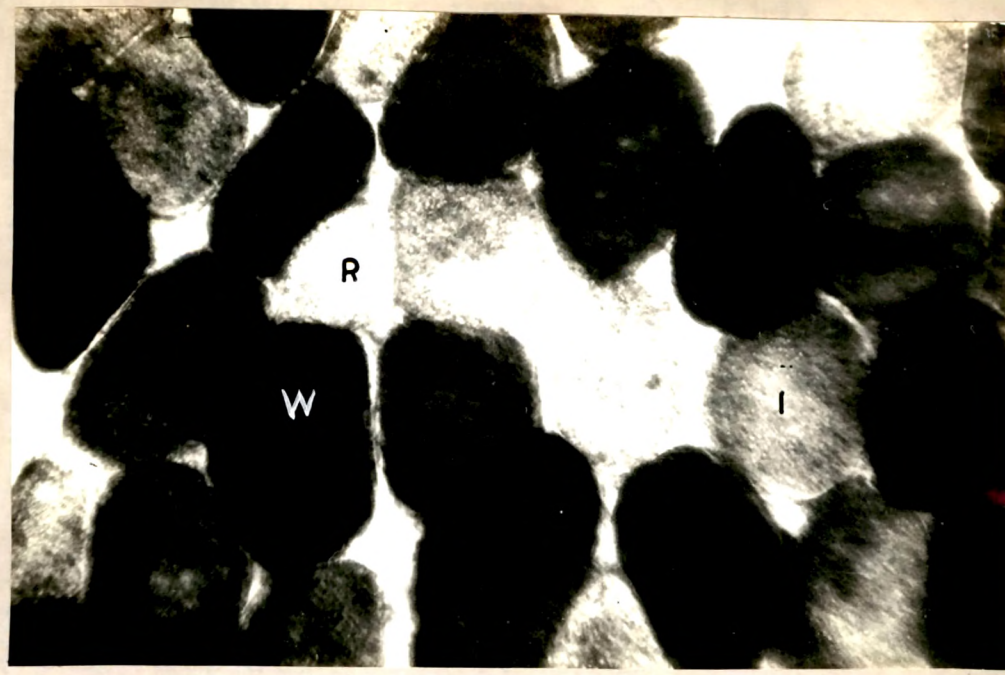

Fig. 3. T.S. of normal human gluteus muscle showing the localization of phosphorylase activity. Note the darkly, lightly and negatively stained fibres. 400X.

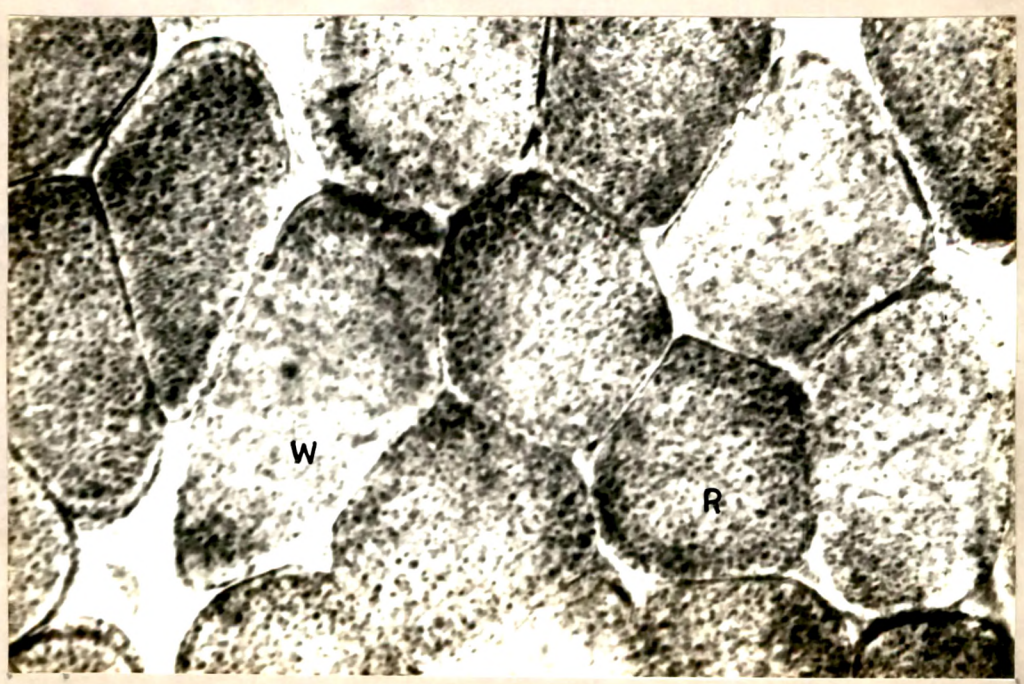

Fig. 4. T. S. of human normal gluteus muscle showing the localization of glucose-6-phosphate dehydrogenase. Red (narrow) fibres (R) show greater activity. 640 X.

Fig. 5. T.S. of normal human gluteus muscle showing the localization of β-hydroxybutyric dehydrogenase activity . Red fibres (R) are darkly stained. 640X.

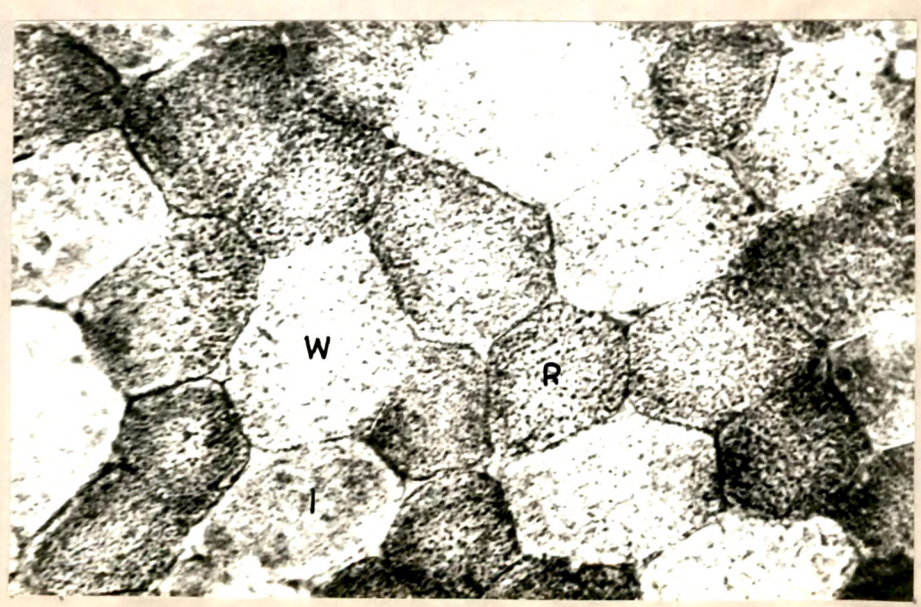

Fig. 6. T.S.of normal human gluteus muscle treated to show the localization of dihydrolipoic dehydrogenase activity. Note the high enzyme activity in the red fibres(R). 400 X.

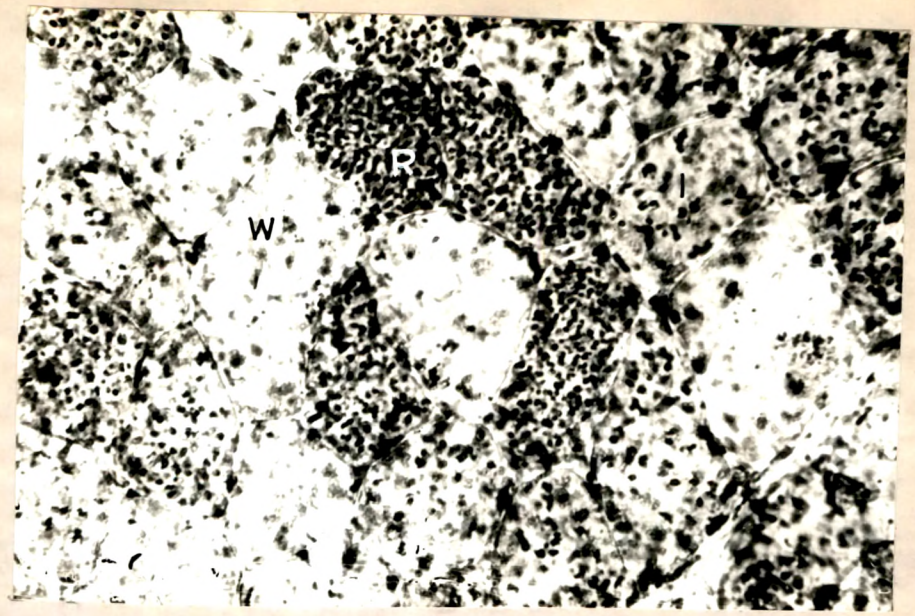

Fig. 7. T.S. of normal human gluteus muscle stained for the demonstration of Tween 20 esterase activity. Red fibres (R) show maximal activity, intermediate ones medium and the white least. 400 X.

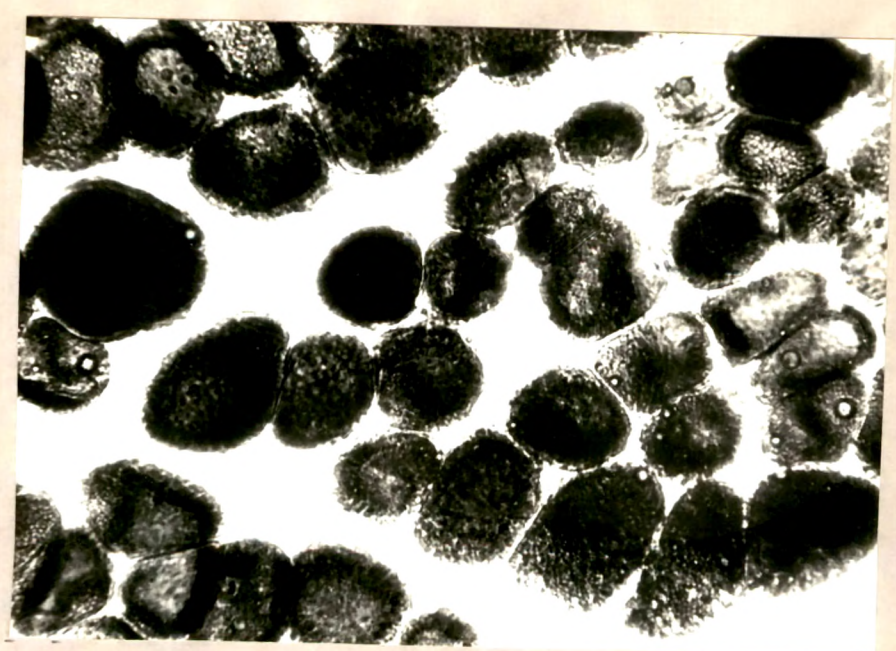

Fig. 8. T.S.of dystrophic human gastrocnemius muscle stained to demonstrate localization of phosphorylase activity. Note that the distinction between the fibre types is not easily possible. 400 X.

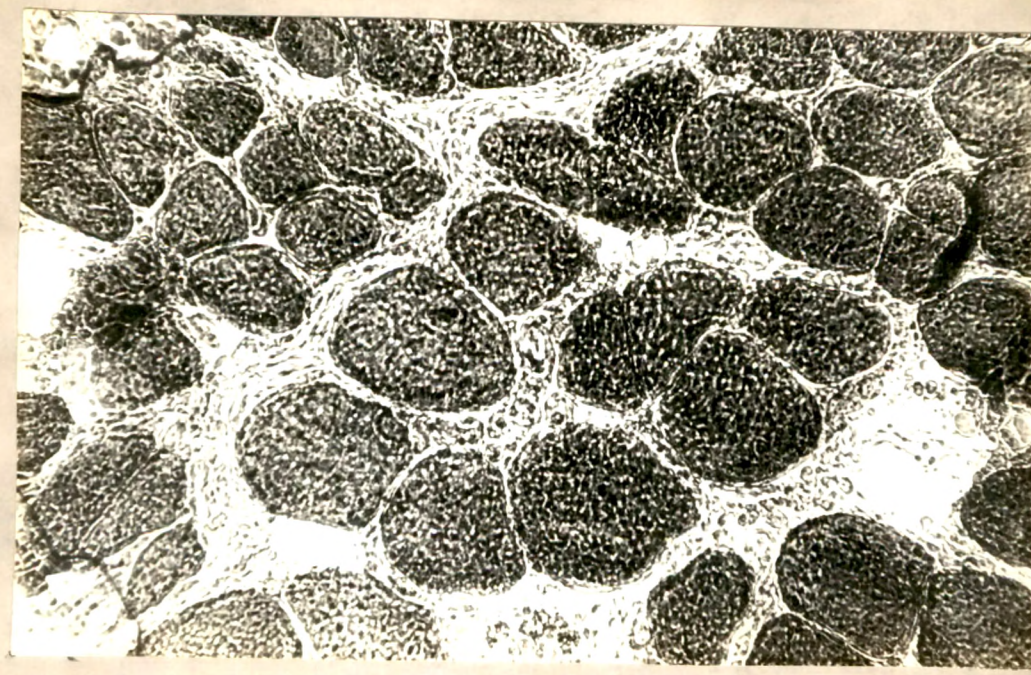

Fig. 9. Dstrophic human gastrocnemius muscle showing the localization of glycogen synthetase activity Note the derangement among the fibres. 400X.

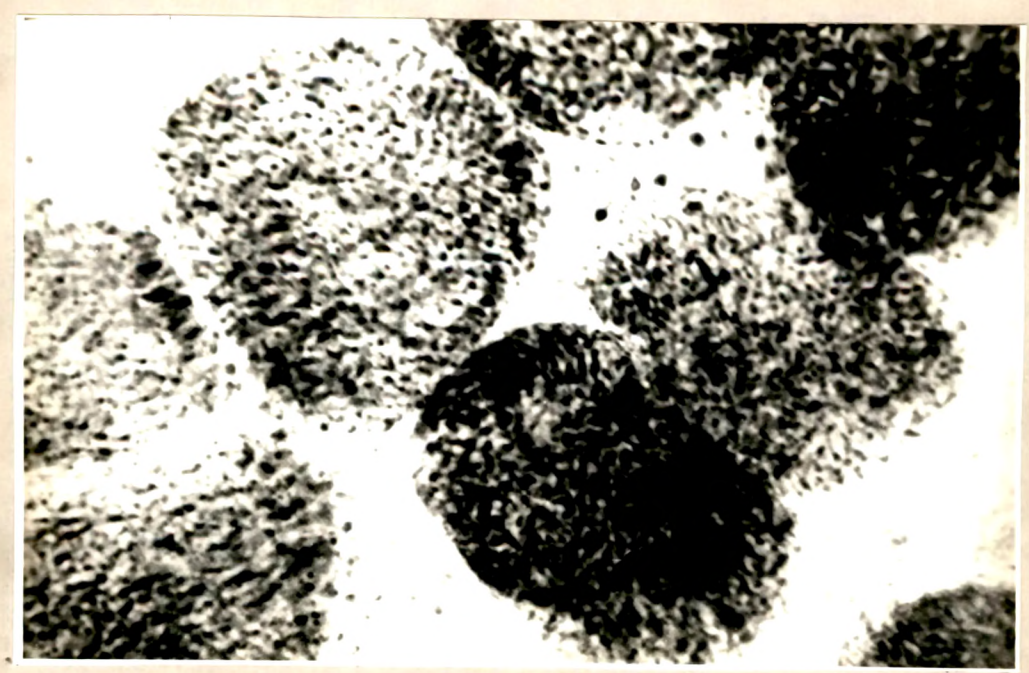

Fig. 10. T.S. of dystrophic human gastrocnemius muscle treated to show the localization of SDH activity. Intense activity is visible in some fibres whereas in others the activity is only moderate. 1008 X.

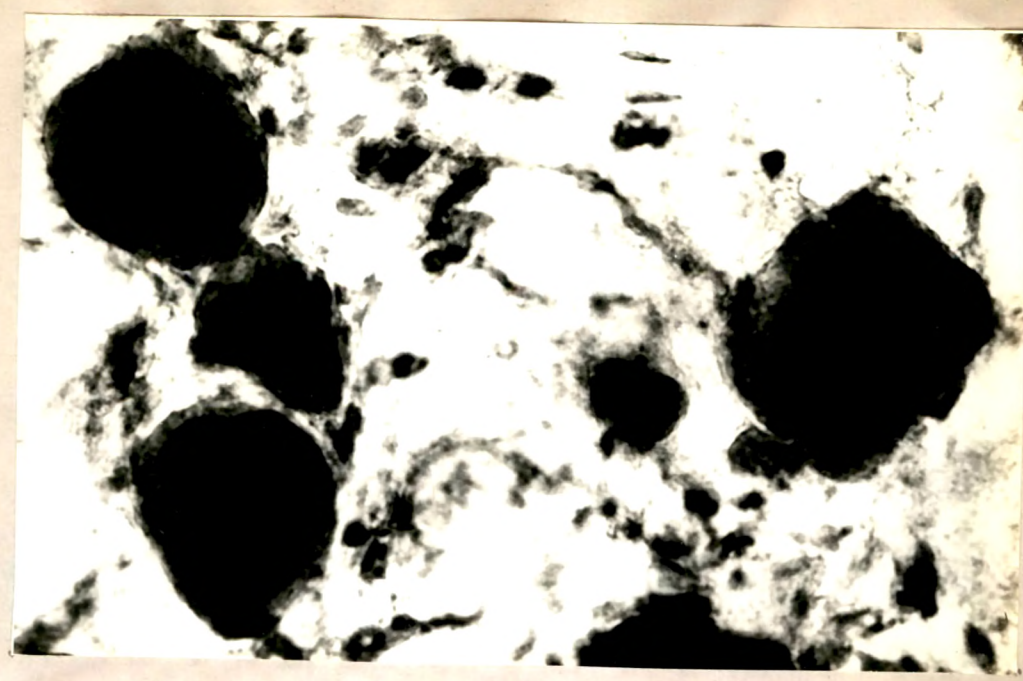

Fig. 11. T.S.of dystrophic human gastrocnemius muscle stained with haematoxylin eosin. Note the increased size of the nuclei, accumulation of connective tissue and reduction in the number of fibres. 400 X.

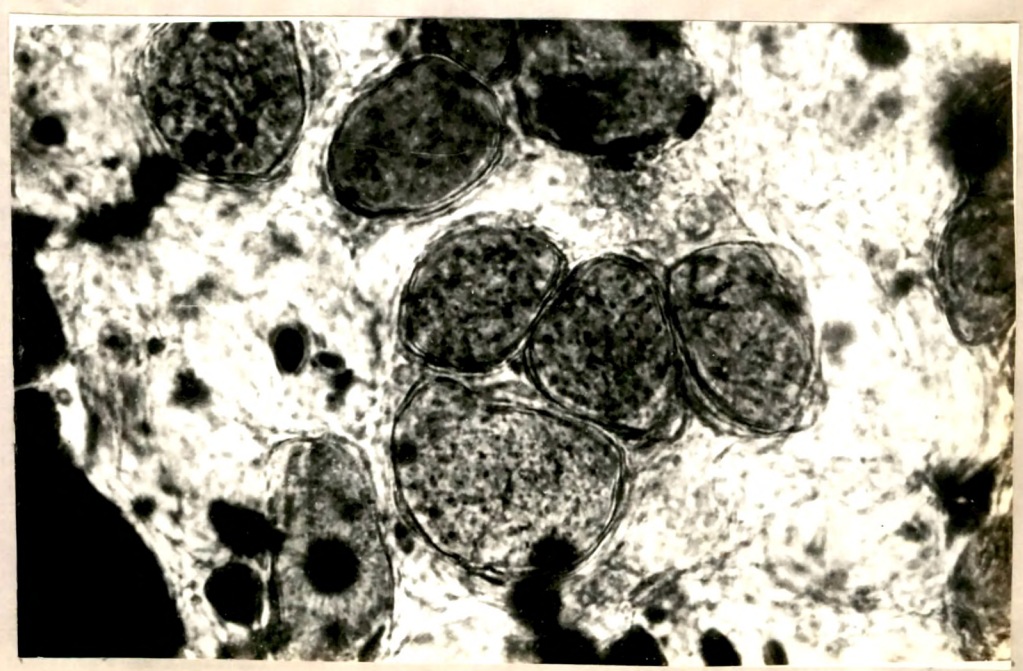

Fig. 12. T.S. of the dystrophic human gastrocnemius muscle stained to demonstrate fat. Note the considerable accumulation of fat in the extracellular space and little inside the fibres. 640 X.

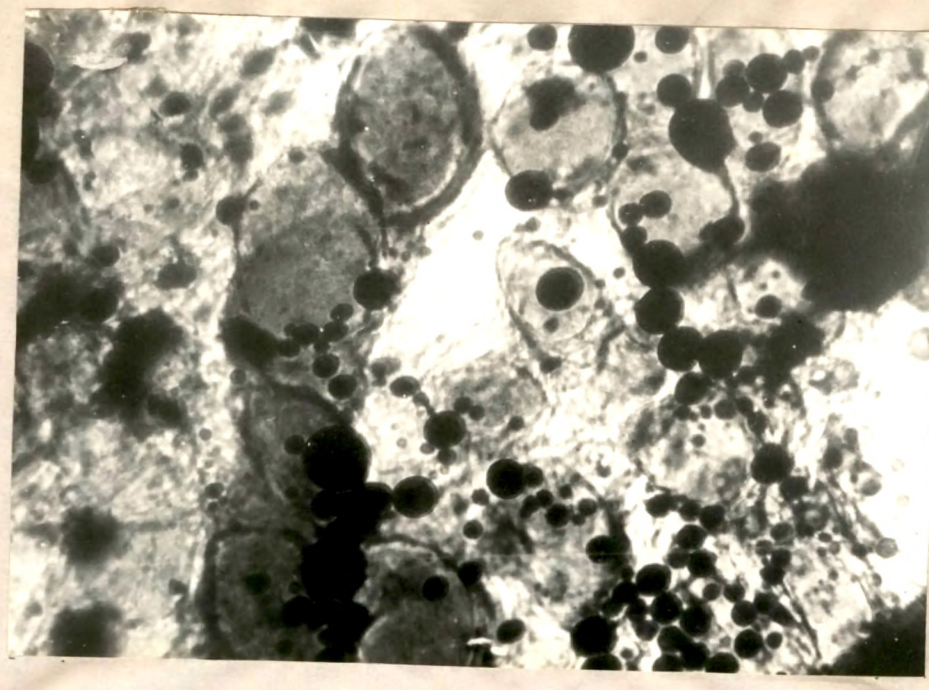

Fig. 13. Same as Figure 12. Note the fat deposition in the form of globules in the extra cellular space. 640 X.

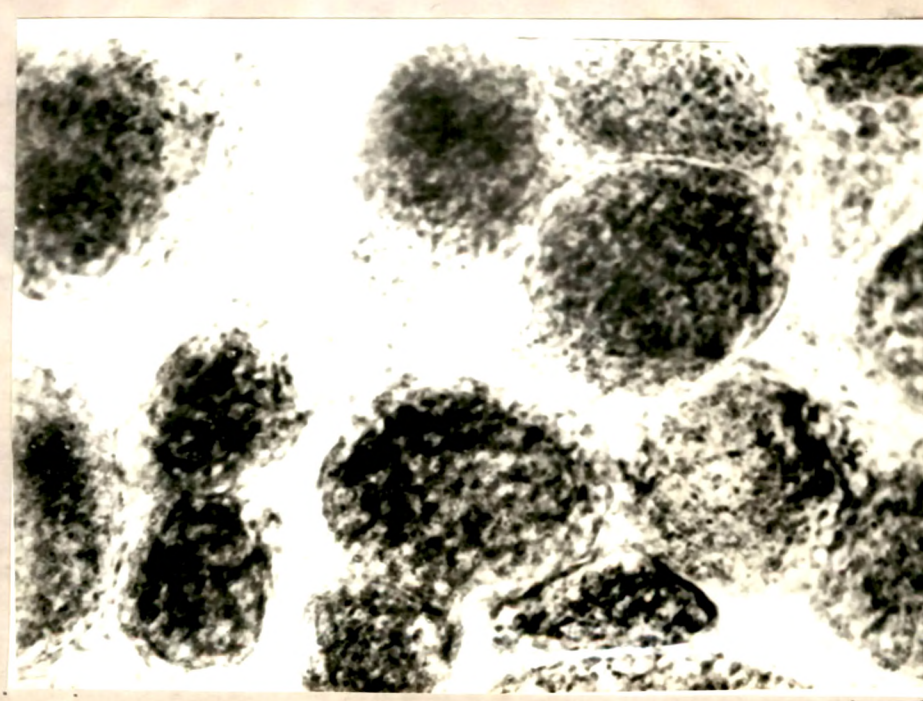

Fig. 14. T.S. of human dystrophic gastrocnemius muscle showing the localization of SDH activity. While some fibres show intense activity others of the same type show only little activity of the enzyme. 640 X.

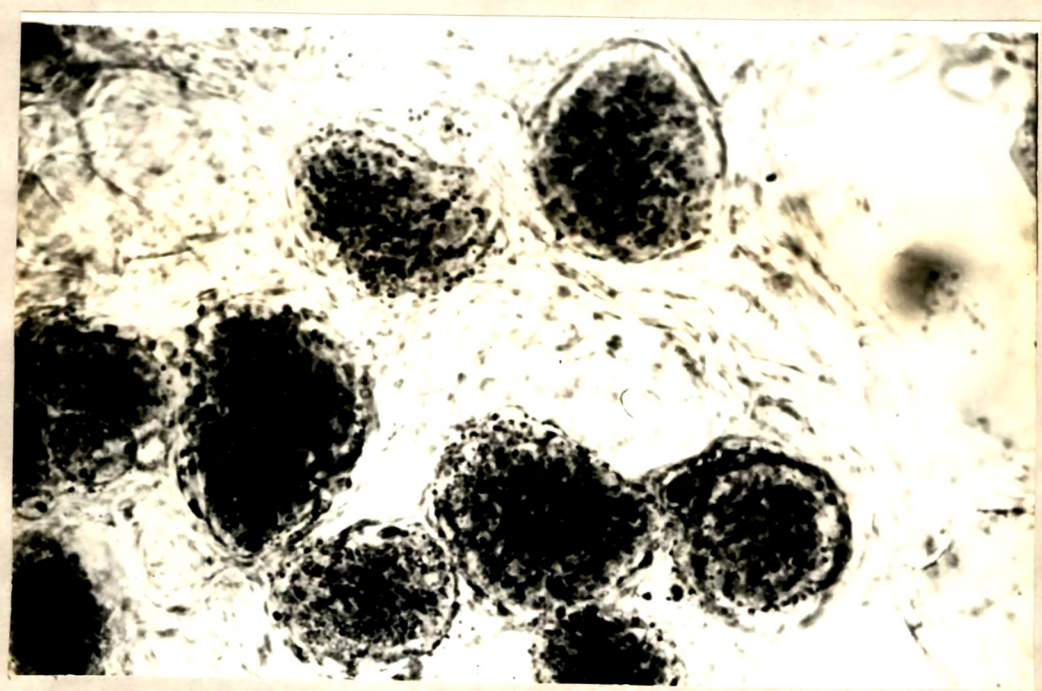

Fig. 15. T.S. of the dystrophic human gastrocnemius muscle treated to show the localization of glucose-6-phosphate dehydrogenase activity . Note the uniform intense activity in all the fibres irrespective of their type. Activity is more prominent towards the centre of each fibre. Connective tissue also shows a positive reaction. 640 X.

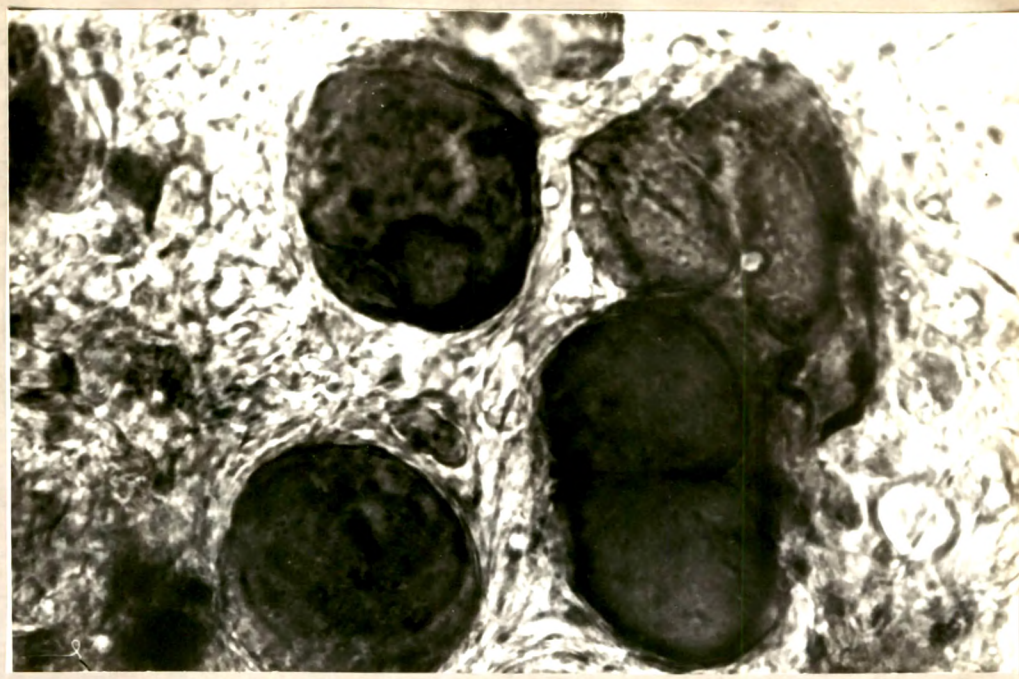

Fig. 16. T.S. of dystrophic human gastrocnemius muscle showing the localization of ATPase activity. An intense reaction is discernible irrespective of the nature of the fibre. Connective tissue stains positive. 640X.

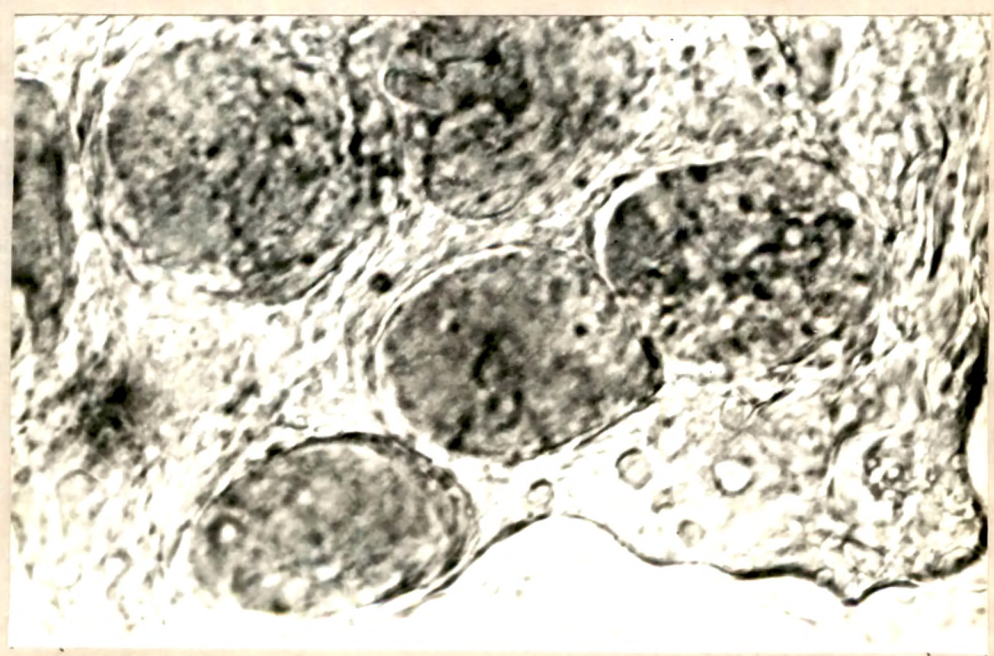

Fig. 17. T.S.of the dystrophic human gastrocnemius muscle treated to demonstrate the localization of acid phosphatase activity. Uniform activity is visible in all the fibres. Connective tissue is also positively stained. 640 X.

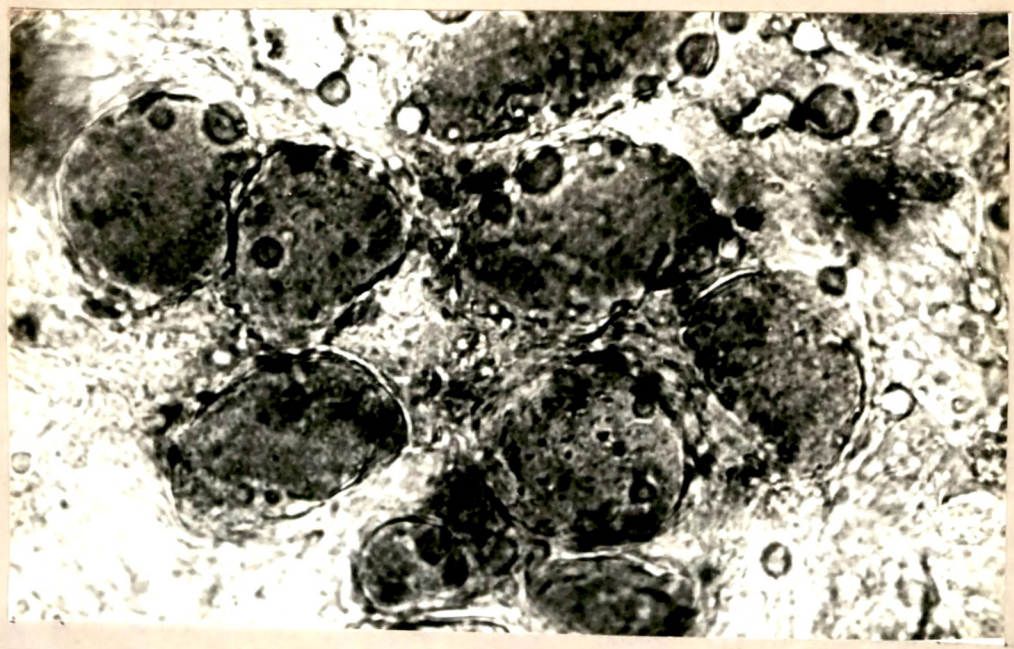

Fig. 18. T.S. of the dystrophic human gastrocnemius muscle stained to demonstrate the localization of alkaline phosphatase activity. Uniform activity is visible in all the fibres. Connective tissue positively stained. 640 X.

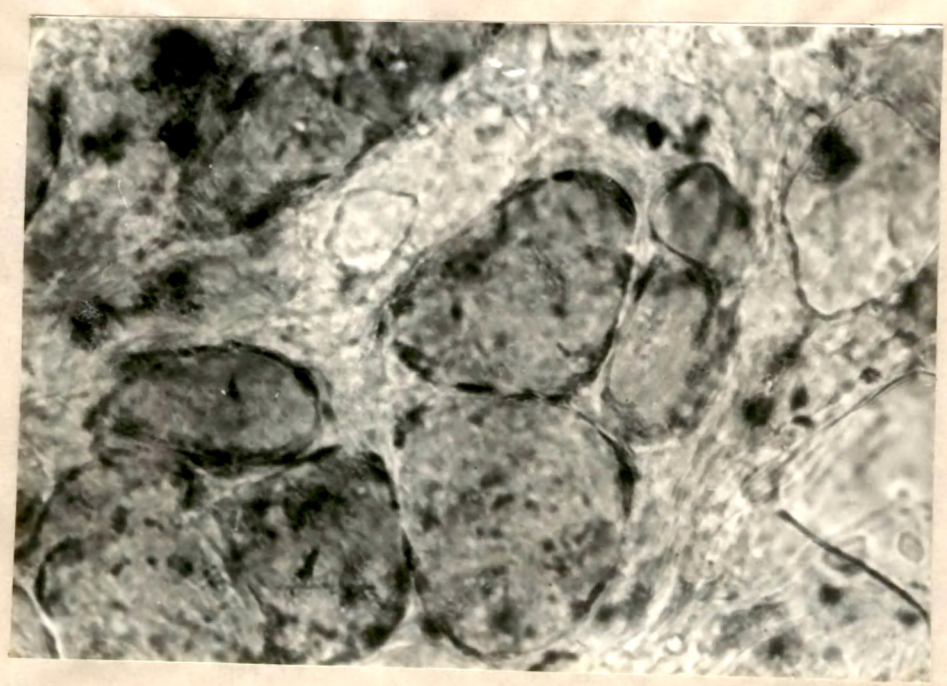

Fig. 19. T.S. of the dystrophic human gastrocnemius muscle treated to show the localization of lipase activity. Note the low activity in the fibres. 640 X.

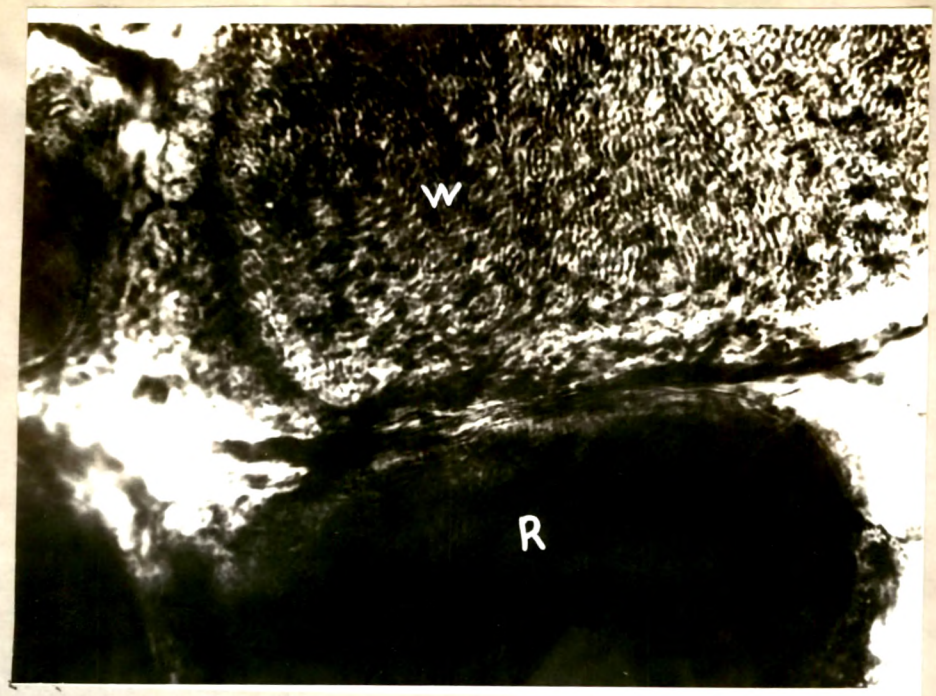

Fig. 20. T.S. of the dystrophic human gluteus muscle stained to demonstrate the localization of glycogen synthetase activity. Note the intense activity in the red fibres (R) and moderate activity in the white fibres (W). 1,008 X.

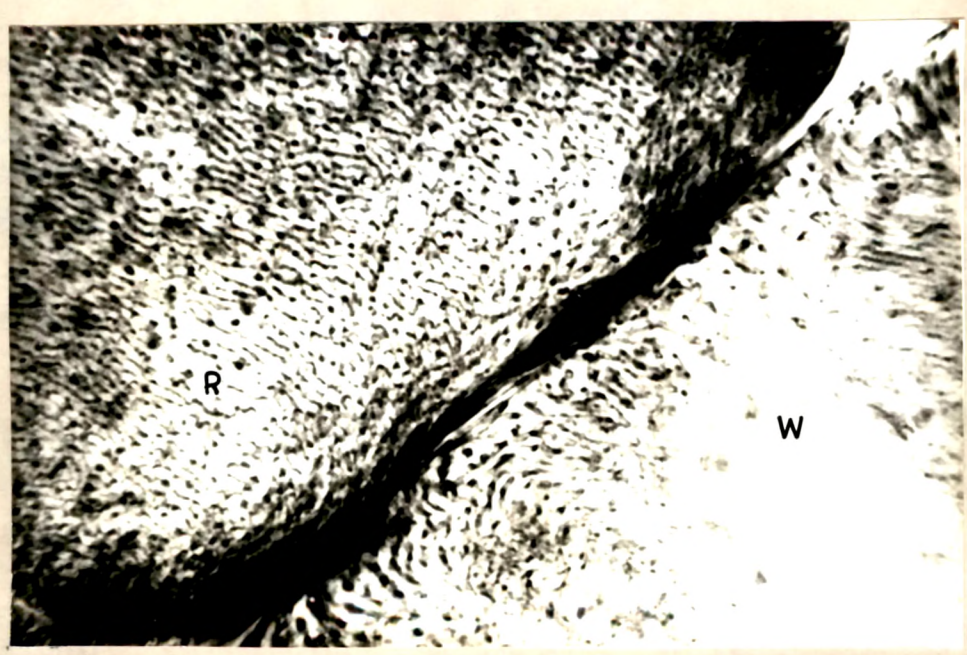

Fig. 21. T.S. of the dystrophic human gastrocnemius muscle showing the localization of glucose-6-phosphate dehydrogenase activity. Relatively intense activity is visible in the red fibres (R). Reticulum is positive in both the red and white fibres (W). The enzyme activity is more towards the periphery of the fibres and connective tissue also shows a positive reaction. 1,008 X.

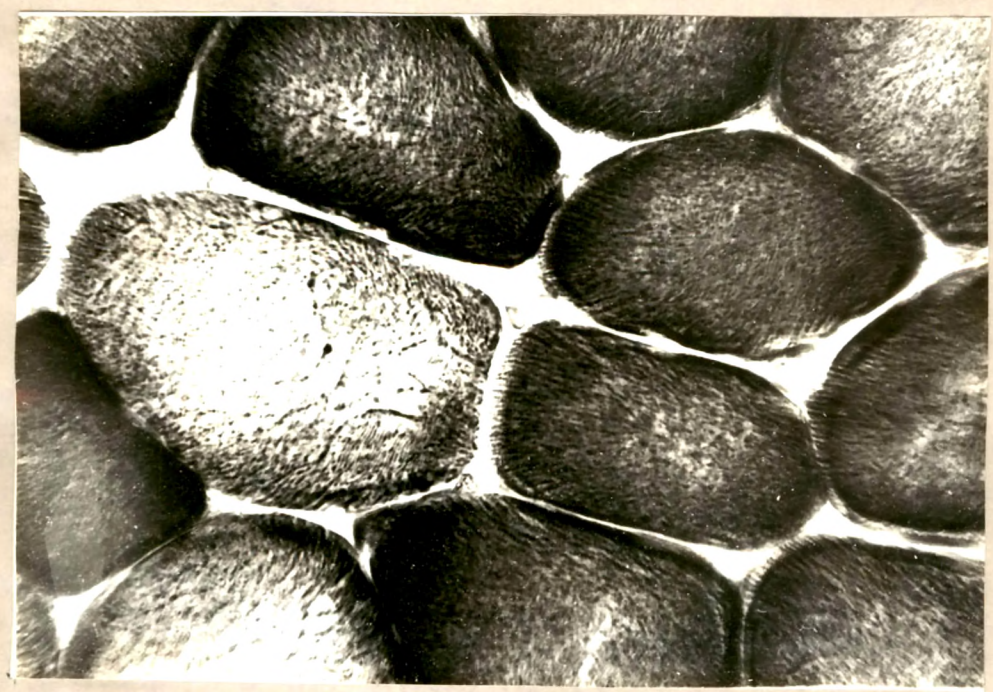

Fig. 22. Same as Figure 22 except that the enzymatic activity demonstrated is of β-hydroxybutyric dehydrogenase. 400X.

than in the white ones. The sarcoplasmic reticulum was moderately stained. The nuclei, connective tissue and blood vessels were however, deeply stained. At lowere pH levels of the activity of the enzyme was found to be consistently and progressively decreasing.

Discussion

The observations made in the present investigation indicate that certain fundamental metabolic differences exist between the normal and dystrophic human muscle. These findings on the human muscle compare favourably with earlier observations on experimentally induced atrophic conditions in the pigeon pectoralis (Chapter 1, 2, and 6). The following are the most striking features that have been found to be common to tissue preparations of human dystrophic muscle and atrophic (induced by denervation or disuse) pigeon breast muscle : (1) Morphological changes in the size and shape of the fibres. (2) Degenerative changes in the fibres. (3) Fatty infiltration and an increase in the extracellular fat. (4) Proliferation of the connective tissue . (5) Increase in the number of nuclei. (6) Increase or decrease as the case may be in the specific activity of some of the enzymes and the content of metabolites within the fibres.

The mechanisms involved in bringing about the difference in the metabolic load and enzyme concentrations in the muscle fibres is suggestive of being a major factor in the

origin of the pathological changes seen in the fibres of either the dystrophic human muscle or the atrophied pigeon breast muscle. This supposition is supported by the finding that in the early days of disuse atrophy, changes in the concentration of the metabolites, glycogen and fat, and of the various enzymes were noted much prior to any morphological alterations (George and Vallyathan, 1962; Chapter 1 and 2).

It has been suggested earlier (Chapter 6) that in the pigeon pectoralis as a result of denervation, the red, lipid loaded and oxidative enzyme rich, tonic fibres become adapted to a glycolytic metabolism and the white, glycogen loaded and glycolytic enzyme rich, tetanic fibres to an oxidative metabolism. In the human dystrophic muscle also, a similar type of transition in the metabolic pattern is encountered. Glycogen, and the enzymes, phosphorylase and UDPG transglucosylase involved in its breakdown and synthesis respectively showed sharp changes in their distribution. The red type of fibres acquired greater concentrations of glycogen unlike in the normal muscle. This increase of glycogen is reflected in the parallel increase of UDPG synthetase. However, the white fibres retained their metabolic content and enzyme activity.

It is noteworthy that there is a considerable accumulation of fat both inter- and intra- cellularly in the dystrophic human muscle, as seen in the atrophied pigeon

breast muscle (Chapters 1 and 6). In two cases of acute dystrophy, the muscle tissue was found to be deeply invaded by fat globules sparing only a very few fibres. This as explained earlier, could be attributed to a diminished rate of utilization or a de novo synthesis by the muscles. In the chapter 5 it was also reported a low capacity for fatty acid oxidation in immobilization atrophy leading to the possibility of fatty acids being synthesized in the muscle.

Evidence in support of increased activity of the pentose cycle dehydrogenases in denervated pigeon pectoralis was provided in chapter 6 and the present observations on the human dystrophic muscle are in agreement. This suggests the possibility of a relationship between the activity of the pentose phosphate pathway and lipid synthesis. The oxidation of glucose in muscle is known to be accelerated by means of TPN dependent enzymes and the resulting reduced coenzyme to be utilized for lipid synthesis (Siperstein, 1958). The enzyme dihydrolipoic dehydrogenase which is important for the generation of acetyl CoA is also responsible for increased synthesis of lipids. A high activity of this enzyme is therefore of significance during muscular dystrophy, for the production of a continuous supply of acetyl Co A, and thereby enhancing lipid synthesis.

Succinic dehydrogenase which has a key role in oxidative metabolism showed markedly increased activity in some of the fibres. Studies on disuse and denervation atrophy

in the pigeon pectoralis (Chapters 2 and 6) demonstrated a marked increase in the enzyme activity in the broad, white fibres, with a reduction in size of the latter and subsequent increase in their mitochondrial population. Thus the mosaic pattern of the fibres seen in the normal pigeon pectoralis was lost. Similar results hold good for the human dystrophic muscle also. The basic histochemical differences observed in the normal muscle become indistinguishable and both the fibre types appear more or less alike with regard to the enzyme activity. It is quite likely that these changes are brought about by inactivation of the muscle which in turn might be exerting an influence on the trophic control of the muscle also. The two distinct types of motor units with different speeds of transmission seen in the white and red fibres may also be becoming functionally similar as a result of dystrophy.

Histochemical attempts to localize lipase activity in the muscle showed negative results even with longer periods of incubation than employed for the normal muscle. Moreover, the biochemical assays undertaken to estimate lipase activity employing the manometric method using tributyrin as substrate, have shown very negligible enzyme activity in muscle (Chapter 9). However, it is claimed by Susheela (personal communication) that in pseudohypertrophic muscular dystrophy, lipase activity was localized in some fibres undergoing longitudinal splitting. The validity of these results

is questionable, since recently Wills (1965) has strongly deprecated the use of water soluble substrates like "Tweens" to be employed as substrates for true lipase in histochemistry. From the present histochemical and biochemical observations it is evident that the enzyme activity in the muscle is very low in dystrophic muscle. These studies are in agreement with our earlier studies on disuse atrophy where the enzyme activity was found to be low during the progressive periods of atrophy. The positive reactions observed in some muscle fibres by Susheela (personal communication) seem to be at an early period of dystrophy when the muscle fibres have a tendency to split longitudinally.

Acid and alkaline phosphatases showed only a slight positive reaction in the muscle fibres, but connective tissue seemed to be considerably more reactive. It is known that acid phosphatase activity is associated with lytic processes in the cell. The increase in its activity during muscular dystrophy may be suggestive of the lytic processes in the degenerating and disintegrating muscle cell. Its increase in the connective tissue may be attributed to the increase in the growth of the connective tissue. The progressive increase in the enzyme activity in the interstitial connective tissue was noted in five of the cases whereas in the other cases it was only moderate. Bourne and Golarz (1959) suggested that dystrophy is primarily a disorder of the connective tissue and the alterations that occur in the muscle fibres

are secondary effects. Since muscle degeneration was significant in the two cases where the increase of connective tissue was little, this suggestion appears to be untenable. The occurrence of alkaline phosphatase in muscle is however, not clear but it is suggestive of some active processes like transphosphorylation reactions or transport of materials.

From the present observations it can be concluded that in muscular dystrophy, many of the morphological and biochemical changes take place in the muscle before dystrophy could be clinically detected. This is evident from two of the cases studied which showed only moderate weakness of the muscle but at the same time highly advanced structural changes when the biopsies were investigated. Therefore a thorough knowledge of the earliest changes that take place in the muscle is essential.

In spite of the numerous interesting investigations on the subject, the fundamental basis for the defects in dystrophy is yet to be discovered. We do not as yet know whether it rests in the intracellular or extracellular organization. What appears likely is that disruption begins in the enzyme complexes inside the cell, and as a consequence of which , there is a proliferation of the extracellular connective tissue and fat leading to the progressive destruction of the muscle fibres. In this context it may be speculated that the acidic lipids probably free fatty acids detected in some of the muscle fibres may exert a toxic effect on the metabolism of the muscle cell and may even bring about the structural disorganization.